

# Amelioration of Sepsis-Induced Liver and Lung Injury by a Superoxide Dismutase Mimetic; Role of TNF- $\alpha$ and Caspase-3

Al-Shaimaa F. Ahmed<sup>1\*</sup>, Asmaa M.A. Bayoumi<sup>2</sup>, Heba M. Eltahir<sup>3</sup>, Sara M.N. Abdel Hafez<sup>4</sup>, Mekky M. Abouzed<sup>3</sup>

<sup>1</sup> Department of Pharmacology and Toxicology, Faculty of Pharmacy, Minia University, 61519 Minia, Egypt

<sup>2</sup> Department of Biochemistry, Faculty of Pharmacy, Minia University, 61519 Minia, Egypt

<sup>3</sup> Department of Pharmacology and Toxicology, Faculty of Pharmacy, Taibah University, Saudi Arabia

<sup>4</sup> Department of Histology and Cell Biology, Faculty of Medicine, Minia University, 61519 Minia, Egypt

Received: November 20, 2019; revised: December 18, 2019; accepted: December 18, 2019

## Abstract

Oxidative stress plays an important role in the development of sepsis and its associated serious consequence leading to multiple organ failure and death. Since the liver and the lungs are among the early affected organs responsible for the mortality in sepsis, we investigated the effect of Tempol, a superoxide dismutase mimetic agent, on lung and liver injuries in a cecal ligation and puncture (CLP)-induced sepsis. Septic animals were given Tempol either before or after CLP procedure. Sepsis outcomes were assessed mainly on the liver and lungs. Separate animal groups were employed for a survival study. CLP resulted in 0% survival, while Tempol pre-or post-treatment led to a 100 % and 40 % survival, respectively. Administration of Tempol resulted in a significant attenuation of sepsis-induced elevation of lipid peroxidation. In the lungs and liver tissues, Tempol resulted in a significant attenuation of elevated tumor necrosis factor- $\alpha$  and caspase-3. Histopathological examination of the lungs and liver confirmed the protective effects of Tempol on these organs. In conclusion: Tempol acts as both prophylactic and therapeutic agent in a rat sepsis model by lowering oxidative stress, inflammatory and apoptotic signals induced by sepsis and reducing lung and liver damage induced by sepsis.

## Key words

Sepsis; CLP, Tempol, NO scavenger, Caspase-3, TNF- $\alpha$ , SOD

## 1. Introduction

Septic shock represents a universal clinical problem, with a mortality rate between 25 % and 90 % [1]. Two hemodynamic phases are established during sepsis, a hyperdynamic- and a hypodynamic phase, which may overlap. The hyperdynamic phase is characterized by macrophages- and neutrophils-mediated massive production of pro-inflammatory cytokines and reactive oxygen species (ROS). The hypodynamic phase represents an anti-inflammatory process that involves decreased lymphocyte proliferation and function and increased rate of apoptosis. Induction of sepsis by cecal ligation and puncture (CLP) model mimics the human clinical disease of perforated appendicitis or diverticulitis. In both disorders, peritonitis is induced as a result of mixed intestinal flora. This model is considered as a standard model for characterization of the pathways involved in sepsis [2].

ROS generation during sepsis activates cell membrane lipid peroxides, which interact with plasma proteins, producing chemotactic agents and increasing vascular permeability. It was reported that superoxide anions, hydrogen peroxide and nitric oxide are produced by septic rats' neutrophils, which are capable of generating the potent oxidant peroxynitrite. This negatively affects the function of the complexes of the respiratory chain in the mitochondria [3]. Interventions that reduce the generation or ameliorate the effects of ROS are

shown to possess beneficial effects in models of septic shock [4].

Due to the major role for ROS in sepsis events, efforts are made to study the effectiveness of free radical scavengers in sepsis [5]. Tempol, an SOD mimetic, is a stable piperidine nitroxide that can penetrate biological membranes and scavenge superoxide anions *in vitro* [6] and *in vivo* [7]. It was also reported that Tempol prevents hemorrhagic shock [8], cardiac fibrosis in diabetic rats [9], endotoxin-induced organ injury in rat [10] and protects the spinal cord mitochondria against oxidative stress damage [11]. The liver and the lungs are among the early affected organs and a leading cause of death in septic patients [12]. The effect of Tempol on a CLP model of sepsis and its mechanism of action has not been fully studied. The aim of the present study is to investigate and compare the effect of pre-treatment and post-treatment of Tempol on 15-days survival of septic rats. To understand the mechanism of protection of Tempol on liver and lung injury induced by sepsis, we studied the effects of Tempol on the liver and lungs of septic animals by assessing oxidative stress as well as markers of inflammation and apoptosis.

## 2. Materials and Methods

### 2.1. Animals and drugs

\* Correspondence: Al-Shaimaa F. Ahmed  
 Tel.: +2 01020018842; Fax: +20 862345631  
 Email Address: [shaimaa.faissal@minia.edu.eg](mailto:shaimaa.faissal@minia.edu.eg)

All animals were housed in accordance with the ARRIVE guidelines and carried out in accordance with the U.K. Animals (Scientific Procedures) Act, 1986 and associated guidelines, EU Directive 2010/63/EU for animal experiments. All experimental procedures were approved by the Research Ethics Committee in the Faculty of Pharmacy, Minia University, Egypt (Permit Number: MPH-12-015).

Female albino Wistar rats ( $200 \pm 30$  g) were purchased from El-Nahda University Animal House (Beni-Suef, Egypt). Upon arrival, they were housed under specific pathogen-free conditions on a 12-h light-dark cycle with free access to food and water for one week before the experiment. Tempol was purchased from Phoenix® (Phoenix Pharmaceuticals, Burlingame, CA, USA). Twenty rats were randomly assigned to four groups, five rats each, as follows: Group 1: sham-operated (sham group); Group 2: septic animals (CLP group); Group 3: CLP rats receiving Tempol (10 mg/kg, *i.p.*) [13] 4 h before surgery (pre-treatment group); and Group 4: CLP rats receiving Tempol (10 mg/kg, *i.p.*) 4 h after surgery (post-treatment group).

## 2.2. Induction of sepsis by CLP

Sepsis was induced by CLP method as previously described [14]. Briefly, freely fed rats were anaesthetized by an *i.p.* injection of a mixture of ketamine (50 mg/kg) and xylazine (10 mg/kg), and then an abdominal incision was made in the lower left quadrant of the body after shaving and disinfecting this part using povidone-iodine solution. The cecum was then exteriorized and ligated with a 0.3 silk surgical suture thread and two punctures were made in the ligated part using an 18-gauge syringe needle. To minimize variations in the severity of sepsis, the length of ligated cecum was kept constant through all septic rats (0.5 cm long). The ligated cecum was squeezed gently and returned back into the abdominal cavity. Sutures were made in two layers and the animals received normal saline solution (subcutaneously) in a dose of 3 ml/100 g for resuscitation. The sham-operated rats were subjected to the same procedure with the exception of the ligation and puncture procedure. Twenty-four hours after surgery, rats were sacrificed and blood was collected by exsanguination then centrifuged to obtain serum samples. The liver and lungs were carefully dissected, washed and divided into two parts; one part was for histopathological examination and the other part was flash frozen and homogenized for assessment of different biochemical markers.

## 2.3. Survival study

In another set of experiment, forty rats (same weight and sex as the previous experiment) were randomly assigned to four groups, ten rats each, as follows: sham group; CLP group; pre-treatment group; and post-treatment group. All rats were allowed to live with free access to water and food and the mortality of rats was calculated daily for 15 days.

## 2.4 Assessment of lipid peroxidation and total nitrates

Malondialdehyde (MDA) content, as a marker of lipid peroxidation, was colorimetrically measured in serum, liver and lung tissue homogenates according to Buege and Aust method [15].

Total nitrates concentration was determined colorimetrically using the Griess reaction [16] after reduction of nitrates to nitrites by cadmium.

## 2.5. Assessment of reduced glutathione (GSH) content

This method depends on the reduction of Ellman's reagent (5, 5-dithio-bis-2-nitro benzoic acid) by the -SH group of GSH in tissue homogenates to form a product 5-thio-2-nitrobenzoic acid, which is measured colorimetrically at 405 nm using Beckman DU-64 UV/VIS spectrophotometer [17]. Results were expressed as  $\mu\text{mol/g}$  liver tissue.

## 2.6. Western blotting

We performed western blotting as previously described [18]. Briefly, for estimation of liver and lung content of TNF- $\alpha$  and caspase-3, tissue was homogenized in a buffer containing 20 mM Tris-HCl (pH 7.5), 0.15 M NaCl, 0.5 % Triton X-100, 0.1 % SDS, 1 mM EDTA, and protease inhibitor cocktail (Nacalai Tesque, Inc., Kyoto, Japan). Then, a volume of tissue homogenate equivalent to 30  $\mu\text{g}$  total protein was subjected to SDS-PAGE under reducing conditions. The SDS-sample buffer contains 62.5 mM Tris-HCl (pH 6.8), 2 % SDS, 0.02 % BPB, 10 % glycerol and 5 %  $\beta$ -mercaptoethanol. Protein bands were transferred to a nitrocellulose membrane using a semi-dry blotter (Bio-Rad) in the presence of a blotting buffer containing 100 mM Tris, 192 mM glycine, and 10% methanol. The blot was subsequently blocked with TBS-T buffer (25 mM Tris-HCl pH 7.5, 150 mM NaCl, 0.05 % Tween-20), and 5 % skim milk powder for 1 h at room temperature. The blot was incubated overnight at 4 °C with the primary antibody (rabbit anti-TNF- $\alpha$ , rabbit anti-caspase-3, or mouse anti-  $\beta$ -actin). Subsequently, incubation with alkaline phosphatase-coupled secondary antibody (anti-rabbit and anti-mouse antibody, respectively) was performed for 1 h at room temperature. Blots were finally analyzed using 5-bromo-4-chloro-3-indolyphosphate (BCIP)/nitro-blue tetrazolium (NBT) colorimetric detection method. Protein bands on the blots were quantified using Image-J software (Image J 1.48V, Wayne Rasband National Institutes of Health, USA).

## 2.7. Histopathological study

Specimens of the liver and lung tissues were removed and fixed in 10 % formal-saline for 24 h and then processed to obtain paraffin blocks, from which 5- $\mu\text{m}$ -thick sections were cut and stained with haematoxylin and eosin (H&E) staining [19]. Images were captured using an Olympus digital camera adapted to BX51 microscope (Olympus, Japan).

A morphometric study was performed for semi-quantitation of data for three parameters [20] by an observer blind to the different experimental groups. All parameters were counted in ten non-overlapping fields per section at power X 400

magnifications from each animal. Measurements were carried out using the Image J software. The parameters were as follows: the mean number of inflammatory cells (neutrophils, lymphocytes and eosinophiles) in liver and lung tissues; the mean number of apoptotic cells (cells with deeply stained cytoplasm and small dense eccentric nuclei) in liver tissues; and the mean number of degenerated areas (containing vacuolated cells) in liver and lung tissues.

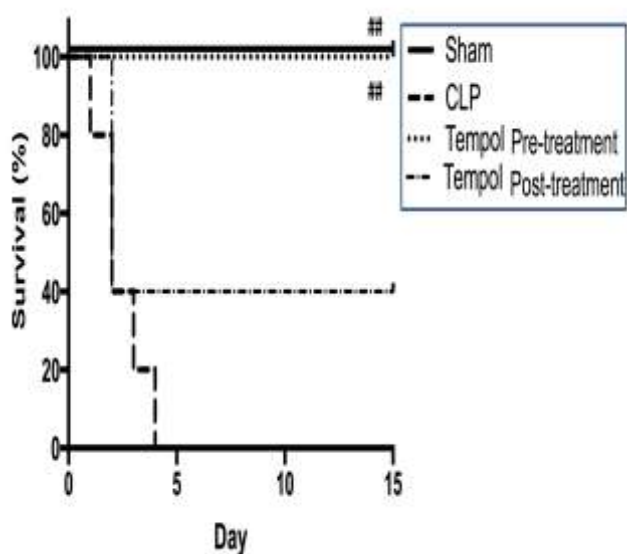
## 2.8. Statistics

All statistical analyses were performed using GraphPad Prism (version 6.0; San Diego, CA, USA). Analysis of Variance (one-way ANOVA) test was used for multiple comparisons followed by Tukey-Kramer post hoc test. Values were expressed as mean  $\pm$  S.E.M. Survival analysis was performed using Log-rank (Mantel-Cox) test. The results were considered statistically significant if the  $p$ -values were  $<0.05$ .

## 3. Results

### 3.1. Tempol improves survival in septic rats

CLP resulted in 0 % survival by the fourth day post-surgery. Interestingly, administration of Tempol 4 h prior to CLP completely prevented mortality and achieved 100 % survival in pre-treatment group. Tempol administration 4 h after surgery resulted in a partial protection against CLP-induced mortality ending by 40 % of animals surviving in post-treatment group. Survival analysis revealed a significant difference ( $p<0.01$ ) in survival between sham group and CLP group as well as between pre-treatment group and CLP group (**Figure 1**).



**Figure 1: Effect of Tempol pre-treatment and post-treatment on survival after induction of sepsis.**

Cecal ligation resulted in reducing the number of surviving rats to reach 0 % survival before day 5. Tempol pre-treatment prevented CLP-induced mortality; whereas post-treatment with Tempol resulted in 40% survival. Mortality was monitored daily for 15 days,  $n=10$ /group. ## Significantly different compared to CLP group at  $p<0.01$ .

### 3.2. Tempol attenuates CLP-induced oxidative stress

Induction of sepsis led to a significant elevation ( $p<0.05$ ) in serum MDA as an indicator for thiobarbituric acid reactive substances (TBARS) compared to sham-operated rats. Administration of Tempol before or after CLP showed a significant attenuation of CLP-induced elevation in serum MDA levels ( $p<0.05$ ) as shown in **Figure 2A**. In addition, lung MDA was significantly increased ( $p<0.05$ ) in response to CLP compared to sham-operated animals. Both pre-treatment and post-treatment with Tempol caused a significant reduction ( $p<0.05$ ) in CLP-induced increase in TBARS in lung tissue as shown in **Figure 2B**. Liver MDA was significantly increased ( $p<0.05$ ) in response to CLP compared to sham-operated animals. Both pre-treatment and post-treatment with Tempol caused a significant reduction ( $p<0.01$  and  $p<0.05$ ; respectively) in CLP-induced increase in TBARS in liver tissue as shown in **Figure 2C**. Pre-treatment group showed a more significant effect of Tempol compared to post-treatment group.

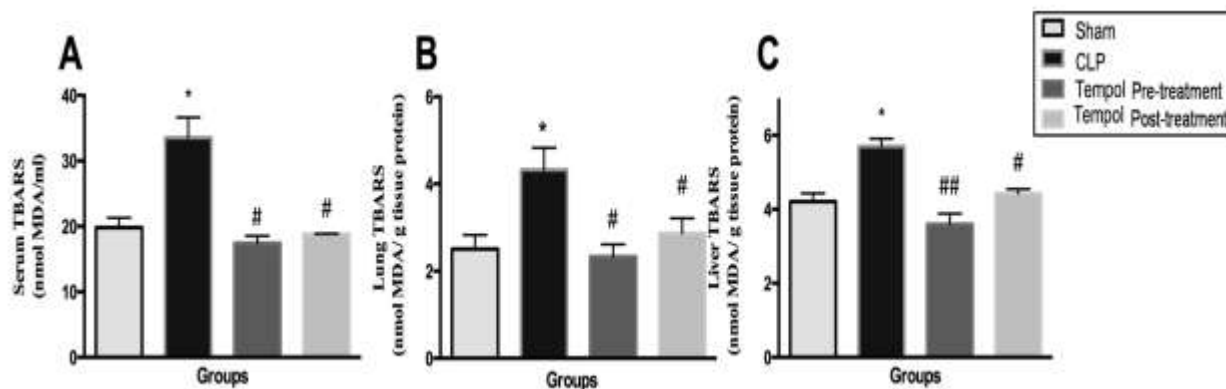
Rats subjected to CLP showed a significantly high level of lung (**Figure 3A**) and liver (**Figure 3B**) nitrates compared to sham rats ( $p<0.001$  and  $p<0.05$ ; respectively). Both lung and liver total nitrates concentration were significantly decreased in the rats pre-treated with Tempol ( $p<0.001$  and  $p<0.01$ ; respectively) compared to CLP group. The lung and liver total nitrates level was significantly reduced ( $p<0.05$  and  $p<0.01$ ; respectively) in Tempol post-treated group compared to CLP group.

In response to sepsis, lung (**Figure 4A**) and liver (**Figure 4B**) GSH contents were significantly depleted compared to sham group ( $p<0.01$  and  $p<0.001$ ; respectively). In lung tissue, only Tempol pre-treated rats showed a GSH level which is significantly different ( $p<0.05$ ) from CLP rats, while Tempol post-treatment did not result in a significant improvement of GSH level compared to CLP rats. In the liver, both Tempol pre- and post-treatments significantly increased GSH levels compared to CLP group ( $p<0.001$ ). Again, pre-treatment group showed a more significant effect of Tempol compared to post-treatment group.

### 3.3. Tempol attenuates CLP-induced inflammatory and apoptotic signals

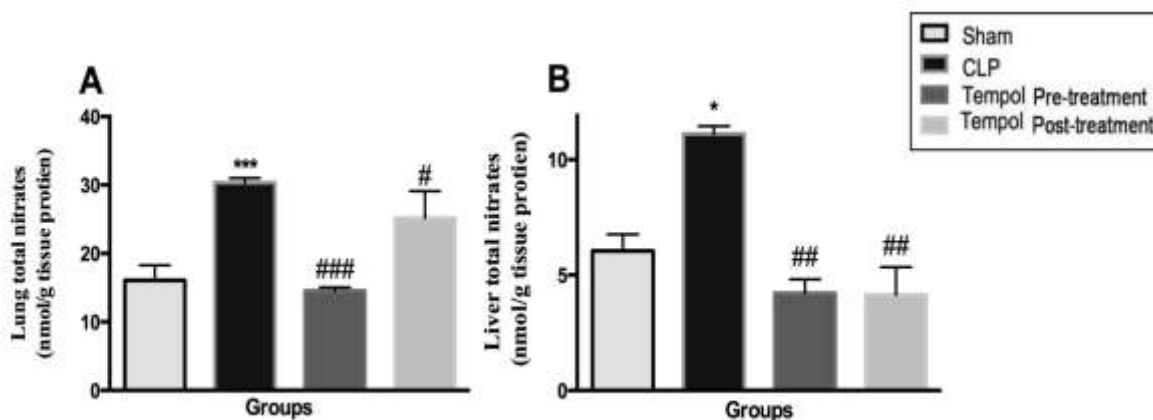
Western blotting analysis revealed a significant increase in TNF- $\alpha$  protein expression in the lungs (**Figure 5A**) and livers (**Figure 5B**) of CLP group ( $p<0.001$ ) compared to sham-operated group. Administration of Tempol either before or after induction of sepsis resulted in a significant reduction of TNF- $\alpha$  in lung and liver tissues ( $p<0.001$ ). This indicates that TNF- $\alpha$  is involved in the mechanism of Tempol protective action against sepsis outcomes.

Caspase-3 protein expression was also increased in the lungs (**Figure 6A**) and livers (**Figure 6B**) of CLP rats ( $p<0.001$ ) compared to sham-operated group. Tempol pre-treatment resulted in an attenuation of CLP-induced apoptosis and showed significant lower levels of caspase-3 in lung and liver tissue ( $p<0.001$ ) compared to CLP rats. In addition, Tempol post-treatment resulted in significant lower levels of caspase-3 in



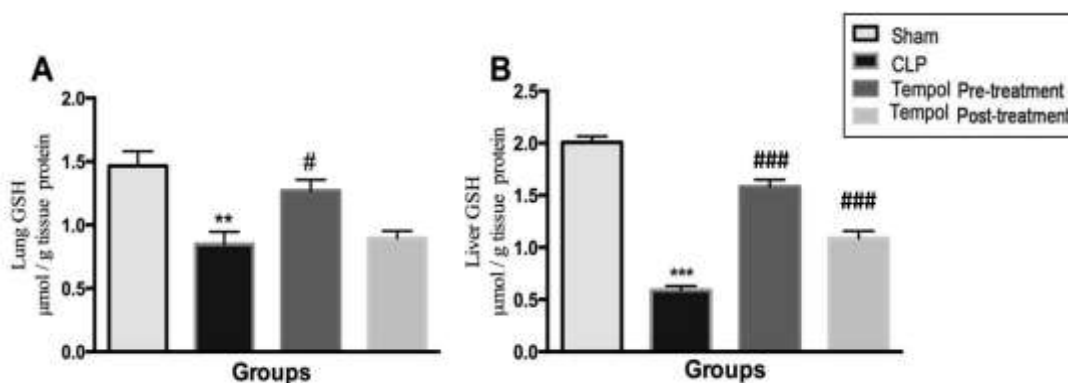
**Figure 2: Effect of Tempol on serum, lung and liver TBARS.**

CLP resulted in a significant increase in serum (A), lung (B) and liver (C) TBARS. Tempol treatment either before or after CLP significantly reduced TBARS levels compared to CLP animals. Data are presented as mean  $\pm$  S.E.M (n=5). \* Significantly different compared to sham group at  $p < 0.05$ ; # Significantly different compared to CLP group at  $p < 0.05$ ; ## Significantly different compared to CLP group at  $p < 0.01$ ; ### Significantly different compared to CLP group at  $p < 0.001$ .



**Figure 3: Effect of Tempol on lung and liver total nitrates.**

Lung and liver tissues from the different groups were assessed for total nitrates concentration. CLP-induced sepsis resulted in a significant increase in lung (A) and liver (B) nitrate. Tempol pre- or post-treatment resulted in a significant reduction in total nitrates concentration compared to CLP group. Data are presented as mean  $\pm$  S.E.M (n=5). \* Significantly different compared to sham group at  $p < 0.05$ ; \*\*\* Significantly different compared to sham group at  $p < 0.001$ ; # Significantly different compared to CLP group at  $p < 0.05$ ; ## Significantly different compared to CLP group at  $p < 0.01$ ; ### Significantly different compared to CLP group at  $p < 0.001$ .



**Figure 4: Effect of Tempol on lung and liver GSH concentration.**

Lung and liver tissues from the different groups were assessed for reduced glutathione concentration. CLP-induced sepsis resulted in a significant reduction in lung (A) and liver (B) GSH. Tempol pre- or post-treatment resulted in a significant elevation in lung and liver GSH compared to CLP treatment. Data are presented as mean  $\pm$  S.E.M (n=5). \*\* Significantly different compared to sham group at  $p < 0.01$ ; \*\*\* Significantly different compared to sham group at  $p < 0.001$ ; # Significantly different compared to CLP group at  $p < 0.05$ ; ### Significantly different compared to CLP group at  $p < 0.001$ .

lung and liver tissues ( $p < 0.001$  and  $p < 0.01$ ; respectively) compared to CLP rats.

### 3.4. Tempol improves the lung and liver histopathological changes associated with CLP-induced sepsis

H&E stained lung sections of sham-operated rats showed normal histology (**Figure 7A**). Sections of CLP group showed severely dilated alveolar sacs with dilated congested inter-alveolar blood vessels as well as a massive thickening of inter-alveolar septa and diffuse inflammatory cells (**Figure 7B**). Tempol pre-treated group showed a marked improvement with fewer inflammatory cells (**Figure 7C**). Tempol post-treated group showed dilatation of alveoli with dilated congested inter-alveolar blood vessels (**Figure 7D**), and thickened inter-alveolar septa containing diffuse inflammatory cell infiltration but much less than that observed in the CLP group. This confirms that Tempol has a protective action against sepsis outcomes, with more potent action observed with pre-treatment than with post-treatment.

Light microscopic examination of the liver sections of the sham group revealed hepatic normal architecture (**Figure 8A**). Various morphological changes were observed in the sections from CLP group. These changes were in the form of dilated thick congested central veins and peri-vascular inflammatory cells. Additionally, apoptotic hepatocytes appeared in the form of small dense eccentric nuclei with dense acidophilic cytoplasm and cells with cytoplasmic vacuolations (**Figure 8B**). Sections of Tempol-pre-treated group showed apparent normal liver architecture with vacuolations in few hepatocytes. Less apoptotic and less inflammatory cell infiltration were also observed (**Figure 8C**). Some sections of Tempol post-treated group displayed focal areas of normal lobar architecture, while others showed disturbed architecture (**Figure 8D**). This again confirms that Tempol pre-treatment is more effective than post-treatment.

**Table 1** quantifies the above-mentioned histopathological observations and shows morphometric results of lung and liver sections.

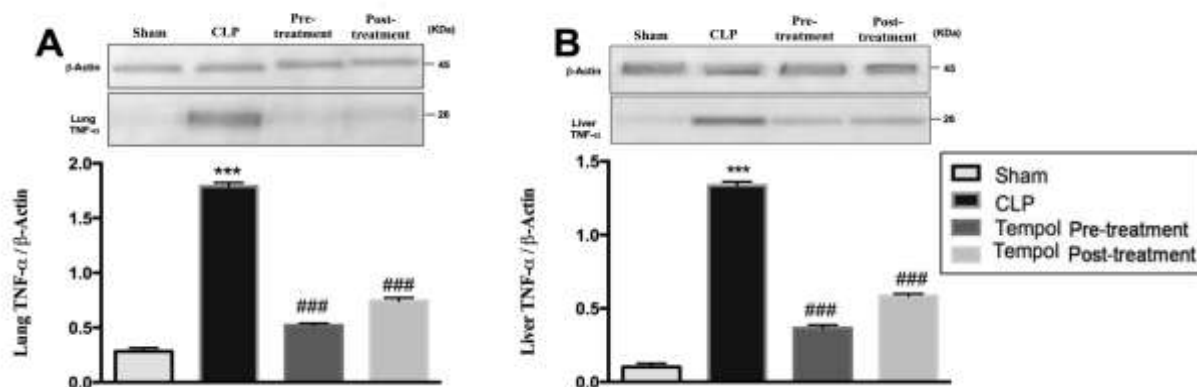
## 4. Discussion

Sepsis leads to multiple organ failure and death, if not promptly treated. Despite the great advances in biomedical research, a little progress has been accomplished in the treatment of sepsis during the past decades. This study showed that induction of sepsis by CLP resulted in a 0 % survival within four days of surgery. Tempol given before- or after sepsis induction led to 100% and 40% survival, respectively. This agrees with the results presented by Liaw *et al.* [21] who observed a two-time improvement of survival rate in septic animals that were treated with Tempol prior to sepsis induction during an 18-hrs experiment. The improved survival in Tempol-treated septic animals observed in our work could be attributed to the protective effects of Tempol observed in many aspects describing lung and liver injury. Similar protective effects of Tempol have been previously reported [13], [22], [23].

In order to emphasize the role of Tempol as an antioxidant and link this effect on the observed improved survival in septic animals, we investigated the effect of Tempol on serum lipid peroxidation level. Both Tempol groups (pre- and post-treatment) showed lower TBARS concentrations compared to CLP group, indicating suppression of sepsis-induced lipid peroxidation by Tempol. These findings are consistent with the well-known mechanism of Tempol as an SOD mimetic agent that can permeate biological membranes and scavenge superoxide anions thus attenuating hydroxyl radicals' production and lipid peroxidation [24]. This effect can be explained in light of previous research showing similar effect of tempol on a model of metabolic syndrome through a reduction of NADPH oxidase expression [25]

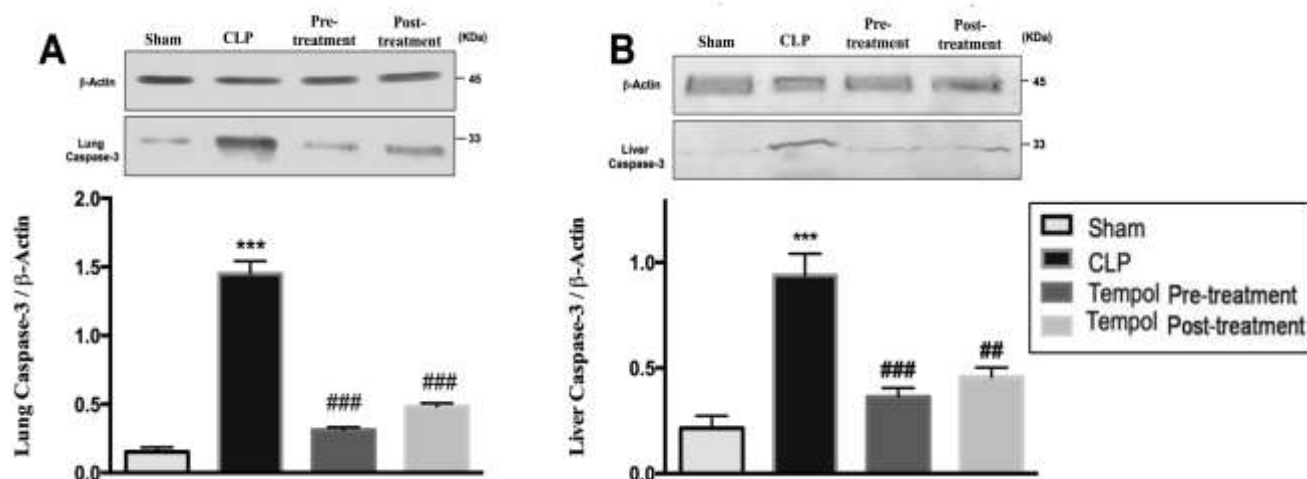
Septic conditions elicit an inflammatory response, where liver-resident cells as well as infiltrated immune cells in the liver and lungs release various inflammatory mediators, such as TNF- $\alpha$ , interleukin- $\beta$ 1 (IL- $\beta$ 1), interleukin-6 (IL-6), interleukin-8 (IL-8), interferon- $\alpha$  (IFN- $\alpha$ ), nitric oxide (NO), and ROS, mediating sepsis-induced organ damage [26]. Reports revealed that TNF- $\alpha$  can induce the production of free radicals, nitric oxide (NO), and eicosanoids from various cells, which can also produce several pathophysiologic changes seen during sepsis and septic shock [27]. In addition to the observed elevation of lung and liver oxidative stress evidenced by increased ROS production and TNF- $\alpha$  protein expression, sepsis depleted lung and hepatic reduced glutathione (GSH), which is responsible for cellular defensive pathways against oxidative as well as nitrosative stress. Several studies have shown depletion of GSH content during sepsis as a result of the excessive oxidative stress condition [28]. The reduction of TNF- $\alpha$  in response to Tempol can be explained by the work of Cuzzocrea *et al.* [29] who showed that tempol reduce TNF- $\alpha$  through the reduction of its upstream transcription factor NF- $\kappa$ B. Nevertheless, TNF- $\alpha$  has an important role in glutathione biosynthesis as it increases glutathione peroxidase activity which converts GSH to its oxidized form (GSSG), hence decreasing the endogenous antioxidant capacity [28]. Tempol treatment led to a reduction in TNF- $\alpha$  protein expression and ROS production and hence, the improvement of GSH level. Consistent with our data that shows a better survival of pre-treatment group versus post-treatment group, the reduction of lung and liver TNF- $\alpha$  and lipid peroxidation and the increase of GSH content were more prominent in Tempol pre-treated than post-treated animals. Tempol caused a reduction in the nitrosative stress in lung and liver homogenates, which can be attributed to a direct effect of Tempol as a nitric oxide scavenger and an indirect action via reducing TNF- $\alpha$ -induced nitric oxide release and restoring the content of the endogenous antioxidant, GSH.

Apoptosis is an essential feature contributing to organ damage in sepsis. Thus, modulation of apoptosis represents a therapeutic possibility for prevention of lung and liver injury [30]. Caspase-3 is an important regulator of apoptosis that becomes activated in the intrinsic and extrinsic apoptotic pathways in response to cytochrome C leakage from the mitochondria [31]. It was reported earlier that Tempol modulates the apoptotic signals by



**Figure 5: Effect of Tempol on lung and liver TNF- $\alpha$  protein expression.**

Western blotting was used to assess TNF- $\alpha$  expression in lung tissue (A) and liver tissue (B). CLP resulted in a significant up-regulation of TNF- $\alpha$  compared to sham animals. Tempol pre- or post-treatment resulted in a significant amelioration of the CLP-induced increase in TNF- $\alpha$  in the lung and liver. Representative western blots are shown in the upper panels. Lower panels show a semi-quantitative analysis presented as mean  $\pm$  S.E.M (n=3). \*\*\* Significantly different compared to sham group at  $p < 0.001$ ; ### significantly different compared to CLP group at  $p < 0.001$ .



**Figure 6: Effect of Tempol on lung and liver caspase-3 protein expression.**

CLP resulted in a significant up-regulation of caspase-3 in the lungs (A) and liver (B) compared to sham animals. Tempol pre- or post-treatment resulted in a significant amelioration of the CLP-induced increase in caspase-3. Representative western blots are shown in the upper panels. Lower panels show a semi-quantitative analysis presented as mean  $\pm$  S.E.M (n=3). \*\*\* Significantly different compared to sham group at  $p < 0.001$ ; ## Significantly different compared to CLP group at  $p < 0.01$ ; ### significantly different compared to CLP group at  $p < 0.001$ .

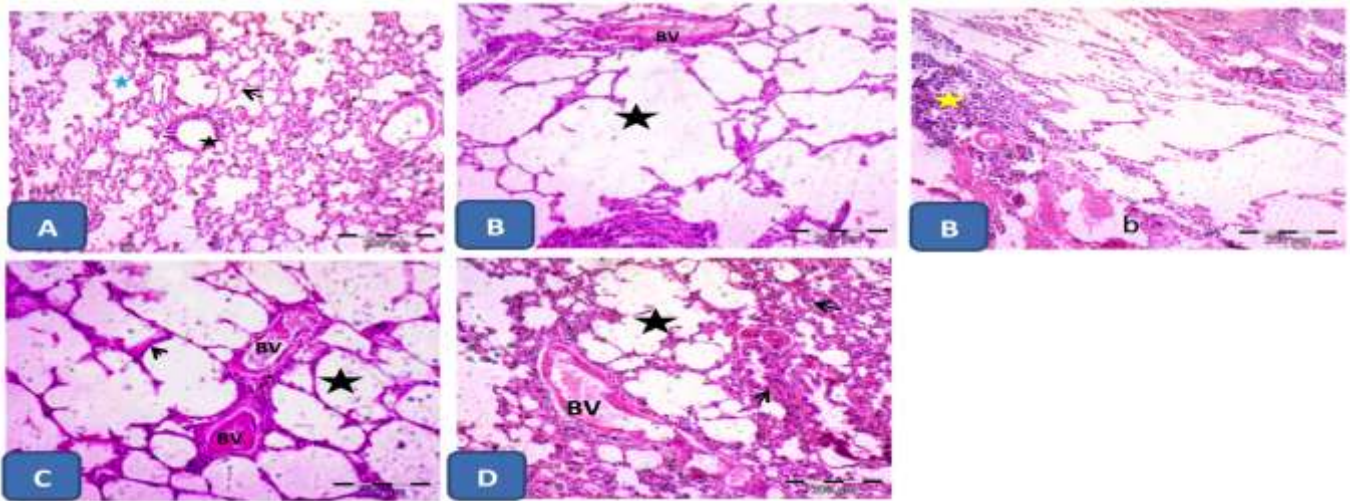
**Table 1: Morphometric results of lung and liver sections in different experimental groups**

	Sham	CLP	Tempol Pre-treatment	Tempol Post-treatment
The mean number of inflammatory cells in liver tissue	0.25 $\pm$ 0.16	26.75 $\pm$ 2.00***	3.88 $\pm$ 0.44###	12.88 $\pm$ 0.92***###
The mean number of inflammatory cells in lung tissue	0.75 $\pm$ 0.25	54.00 $\pm$ 1.16***	17.25 $\pm$ 1.41***###	33.63 $\pm$ 1.18***###
The mean number of apoptotic cells in liver tissue	0.75 $\pm$ 0.31	31.87 $\pm$ 0.98***	7.38 $\pm$ 0.57***###	21.75 $\pm$ 0.75***###
The mean number of degenerated areas in liver tissue	0.25 $\pm$ 0.16	10.63 $\pm$ 0.86 ***	2.25 $\pm$ 0.37**###	4.87 $\pm$ 0.23***##
The mean number of degenerated areas in lung tissue	0.37 $\pm$ 0.18	16.50 $\pm$ 1.18***	2.62 $\pm$ 0.49###	7.50 $\pm$ 0.62***###

Data are representing morphometric values obtained from lung and liver sections of the different experimental groups.

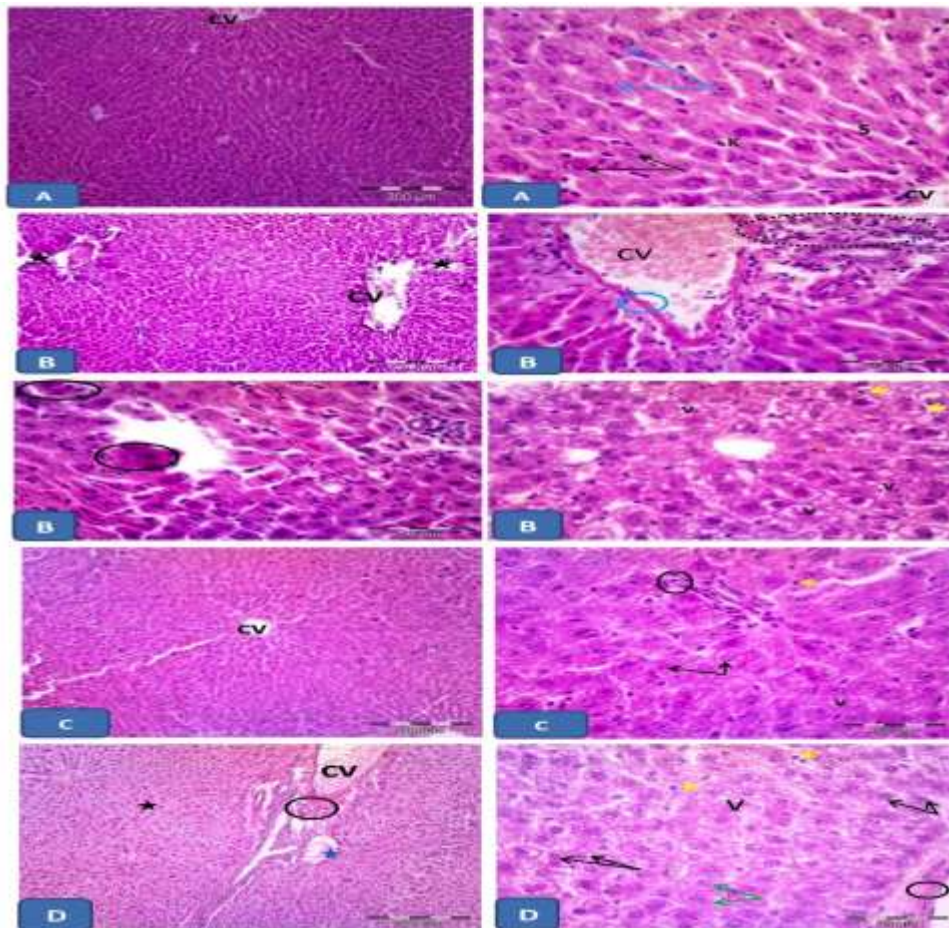
Data are presented as mean  $\pm$  S.E.M (n=5).

\*\* Significantly different compared to sham group at  $p < 0.01$ ; \*\*\* Significantly different compared to sham group at  $p < 0.001$ ; ## Significantly different compared to CLP group at  $p < 0.01$ ; ### Significantly different compared to CLP group at  $p < 0.001$



**Figure 7: Histopathological examination of lung tissue in different groups using H&E staining.**

Representative photomicrographs of sections of a rat lung from sham group (A) showing normal bronchiole (black star), alveoli (blue arrow) and thin inter-alveolar septa (black arrow). Sections from CLP group (B) show severe dilated alveolar sac (black star) with dilated congested inter-alveolar blood vessels (BV). Massive thickening of inter-alveolar septa (yellow star) is clearly noticed with diffuse inflammatory cells. Notice the rupture bronchiole (b). C: A section from Tempol pre-treated group showing some dilatation of alveoli (star) and congested blood vessels (BV) but with more or less normal inter-alveolar septa (arrow) with little inflammatory cell infiltration. D: represents a section from Tempol post-treated group showing dilatation of alveoli (star) with dilated congested blood vessels (BV). Notice the thickened inter-alveolar septa (arrow) containing diffuse inflammatory cell infiltration.



**Figure 8: Histopathological examination of liver tissue in different groups using H&E staining.**

**A:** representative photomicrographs of liver sections of sham group showing normal lobular architecture formed of cords of acidophilic hepatocytes radiated from the central vein (CV). Notice the rounded vesicular nuclei (black arrows) of the hepatocytes. Some hepatic cells are displayed with two nuclei (blue arrow). Notice the blood sinusoids (S) in-between the hepatic cells. Kupffer cells (K) hanging inside the blood sinusoids. **B:** representative photomicrographs of liver sections of the CLP group showing loss of normal hepatic architecture (stars) with dilated congested central vein (CV) and thick wall (blue circle). Notice the perivascular inflammatory cells (circle). Some hepatocytes appear in groups and show dark nuclei with deeply stained cytoplasm (circles). Most hepatocytes show variable amount of cytoplasmic vacuolations (V). Apoptotic cells (yellow arrow) are frequently seen. **C:** representative photomicrographs of liver sections of Tempol-pre-treated rats, showing apparent normal lobular architecture. Hepatocytes radiated from apparent normal central vein (CV). Most hepatocytes (arrows) appear with vesicular nuclei. Very few vacuolations (V) appear in few hepatocytes. Less apoptotic (yellow arrow) and less inflammatory cell infiltration are seen (circle). **D:** Representative photomicrographs of the liver sections of Tempol-post treated group, showing focal areas of normal lobular architecture (black star) while other areas show disturbed lobular architecture (blue arrow). Dilated congested central vein (CV) and perivascular inflammatory cells (circle) are noticed. Some hepatocytes (green arrows) appear with vesicular nuclei, while others show dark nuclei (black arrows). Vacuolations (V) appear in most hepatocytes. Apoptotic cells are also seen (circle). Notice the thickened central vein (CV).

modifying some apoptotic mechanisms [9]. One possible explanation for sepsis-induced apoptosis is the oxidative stress evolved in this condition. The observed ability of Tempol to normalize caspase-3 levels in Tempol-treated septic animals has also been shown before in carbon tetrachloride-induced hepatotoxicity [32] as well as nephrotoxicity [33].

In addition to the biochemical changes observed with sepsis and Tempol treatment, our work demonstrated severe morphological changes within liver and lung tissues due to CLP. These changes were in the form of dilated congested blood vessels, apoptosis, inflammatory cells and degenerated areas. These findings are in line with Yang *et al.* (2017) who reported that liver injury accompanied CLP-induced sepsis due to increased levels of hepatic enzymes, ALT and AST, which were considered as indicators to impaired hepatic membranes with subsequent severe hepatic injury [34]. These hepatocellular injuries were also associated with hepatocyte apoptosis, necrosis, and inflammatory cell infiltration [26].

The Lungs were also reported as one of the most vulnerable tissues during sepsis [35]. The severe pulmonary inflammation, vascular permeability, diffuse inter-alveolar septa, inflammatory cells and oedema within the lungs were detected in septicaemia (CLP group) consistent with previous findings [36]. When Tempol was administered to septic rats, there was an attenuation of all these previous changes. Collectively, it was clearly noticed that Tempol protective effect was more pronounced if given before CLP than after CLP. This can be explained by the ability of Tempol to support and improve the endogenous antioxidant capacity of the cells, which render them more resistant against the oxidative stress induced by sepsis. Our histopathological findings were supported by morphometric analysis results.

## 5. Conclusion

This study presents Tempol as an effective molecule in alleviating the evoked oxidative stress condition by supporting the endogenous antioxidant machinery and scavenging free radicals, and consequently ameliorating sepsis-induced lung and liver injury. Further research is needed to study the impact of earlier post-treatment of Tempol on lung and liver injury as well as on other affected organs during sepsis.

## Acknowledgement

The authors would like to thank Sarah S. Abdel Hamid and Asmaa Soliman Hammad, Department of Pharmacology and Toxicology, Faculty of Pharmacy, Minia University for their technical help.

## Conflict Of Interest Statement

The authors declare that there are no conflicts of interest.

## Funding

This research received no specific grant from any funding agency in the public, commercial, or not-for-profit sectors.

## References

- [1] Martin GS, Mannino DM, Eaton S, *et al.* The epidemiology of sepsis in the United States from 1979 through 2000. *N Engl J Med.* 2003 Apr 17;348(16):1546-54.
- [2] Remick DG, Bolgos GR, Siddiqui J, *et al.* Six at six: interleukin-6 measured 6 h after the initiation of sepsis predicts mortality over 3 days. *Shock.* 2002 Jun;17(6):463-7.
- [3] Cassina A, Radi R. Differential inhibitory action of nitric oxide and peroxynitrite on mitochondrial electron transport. *Arch Biochem Biophys.* 1996 Apr 15;328(2):309-16.
- [4] Szabo C, Zingarelli B, O'Connor M, *et al.* DNA strand breakage, activation of poly (ADP-ribose) synthetase, and cellular energy depletion are involved in the cytotoxicity of macrophages and smooth muscle cells exposed to peroxynitrite. *Proc Natl Acad Sci U S A.* 1996 Mar 5;93(5):1753-8.
- [5] Pinsky MR. Antioxidant therapy for severe sepsis: promise and perspective. *Crit Care Med.* 2003 Nov;31(11):2697-8.
- [6] Pogrebniak H, Matthews W, Mitchell J, *et al.* Spin trap protection from tumor necrosis factor cytotoxicity. *J Surg Res.* 1991 May;50(5):469-74.
- [7] Wang W, Jittikanont S, Falk SA, *et al.* Interaction among nitric oxide, reactive oxygen species, and antioxidants during endotoxemia-related acute renal failure. *Am J Physiol Renal Physiol.* 2003 Mar;284(3):F532-7.
- [8] Novelli GP. Oxygen radicals in experimental shock: effects of spin-trapping nitrones in ameliorating shock pathophysiology. *Crit Care Med.* 1992 Apr;20(4):499-507.
- [9] Taye A, Abouzied MM, Mohafez OM. Tempol ameliorates cardiac fibrosis in streptozotocin-induced diabetic rats: role of oxidative stress in diabetic cardiomyopathy. *Naunyn-Schmiedeberg's archives of pharmacology.* 2013 Dec;386(12):1071-80.
- [10] Leach M, Frank S, Olbrich A, *et al.* Decline in the expression of copper/zinc superoxide dismutase in the kidney of rats with endotoxic shock: effects of the superoxide anion radical scavenger, tempol, on organ injury. *Br J Pharmacol.* 1998 Oct;125(4):817-25.
- [11] Xiong Y, Singh IN, Hall ED. Tempol protection of spinal cord mitochondria from peroxynitrite-induced oxidative damage. *Free Radical Research.* 2009 2009/01/01;43(6):604-612.
- [12] Fujishima S. Organ dysfunction as a new standard for defining sepsis. *Inflamm Regen.* 2016;36:24.
- [13] Yuksel BC, Serdar SE, Tuncel A, *et al.* Effect of tempol, a membrane-permeable radical scavenger, on mesenteric blood flow and organ injury in a murine cecal ligation and puncture model of septic shock. *Eur Surg Res.* 2009;43(2):219-27.
- [14] Nemzek JA, Hugunin KMS, Opp MR. Modeling Sepsis in the Laboratory: Merging Sound Science with Animal Well-Being. *Comparative Medicine.* 2008 04/08/15/received 10/03/11/14/accepted;58(2):120-128.
- [15] Buege JA, Aust SD. Microsomal lipid peroxidation. *Methods Enzymol.* 1978;52:302-10.
- [16] Peter G. Bemerkungen zu der Abhandlung der HH. Weselsky und Benedikt "Ueber einige Azoverbindungen". *Berichte der deutschen chemischen Gesellschaft.* 1879;12(1):426-428.
- [17] Beutler E, Duron O, Kelly BM. Improved method for the determination of blood glutathione. *J Lab Clin Med.* 1963 May;61:882-8.
- [18] Ewees MG, Messiha BAS, Abdel-Bakky MS, *et al.* Tempol, a superoxide dismutase mimetic agent, reduces cisplatin-induced nephrotoxicity in rats. *Drug Chem Toxicol.* 2018 Aug 1:1-8.
- [19] Bancroft JD, Gamble M. Theory and practice of histological techniques. *Elsevier Health Sciences;* 2008.
- [20] Tulic MK, Sly PD, Andrews D, *et al.* Thymic indoleamine 2, 3-dioxygenase-positive eosinophils in young children: potential role in maturation of the naive immune system. *The American journal of pathology.* 2009;175(5):2043-2052.
- [21] Liaw WJ, Chen TH, Lai ZZ, *et al.* Effects of a membrane-permeable radical scavenger, Tempol, on intraperitoneal sepsis-induced organ injury in rats. *Shock.* 2005 Jan;23(1):88-96.
- [22] Abouzied MM, Eltahir HM, Taye A, *et al.* Experimental evidence for the therapeutic potential of tempol in the treatment of acute liver injury. *Molecular and cellular biochemistry.* 2016 Jan;411(1-2):107-15.
- [23] Mota-Filipe H, McDonald MC, Cuzzocrea S, *et al.* A membrane-permeable radical scavenger reduces the organ injury in hemorrhagic shock. *Shock.* 1999 Oct;12(4):255-61.



- [24] Cuzzocrea S, McDonald MC, Mazzon E, et al. Beneficial effects of tempol, a membrane-permeable radical scavenger, on the multiple organ failure induced by zymosan in the rat. *Crit Care Med*. 2001 Jan;29(1):102-11.
- [25] Cannizzo B, Quesada I, Militello R, et al. Tempol attenuates atherosclerosis associated with metabolic syndrome via decreased vascular inflammation and NADPH-2 oxidase expression. *Free Radic Res*. 2014 May;48(5):526-33.
- [26] Yan J, Li S, Li S. The role of the liver in sepsis. *Int Rev Immunol*. 2014 Nov-Dec;33(6):498-510.
- [27] Bhattacharyya J, Biswas S, Datta AG. Mode of action of endotoxin: role of free radicals and antioxidants. *Curr Med Chem*. 2004 Feb;11(3):359-68.
- [28] Biolo G, Antonione R, De Cicco M. Glutathione metabolism in sepsis. *Crit Care Med*. 2007 Sep;35(9 Suppl):S591-5.
- [29] Cuzzocrea S, Pisano B, Dugo L, et al. Tempol reduces the activation of nuclear factor-kappaB in acute inflammation. *Free Radic Res*. 2004 Aug;38(8):813-9.
- [30] Yoon JH, Gores GJ. Death receptor-mediated apoptosis and the liver. *J Hepatol*. 2002 Sep;37(3):400-10.
- [31] Hotchkiss RS, Tinsley KW, Karl IE. Role of apoptotic cell death in sepsis. *Scand J Infect Dis*. 2003;35(9):585-92.
- [32] Abdel-Hamid NM, Wahid A, Mohamed EM, et al. New pathways driving the experimental hepatoprotective action of tempol (4-hydroxy-2,2,6,6-tetramethylpiperidine-1-oxyl) against acute hepatotoxicity. *Biomedicine & pharmacotherapy = Biomedecine & pharmacotherapie*. 2016 Apr;79:215-21.
- [33] Zhang G, Wang Q, Zhou Q, et al. Protective Effect of Tempol on Acute Kidney Injury Through PI3K/Akt/Nrf2 Signaling Pathway. *Kidney & blood pressure research*. 2016;41(2):129-38.
- [34] Yang J-x, Li Y-l, Shi N-c. Attenuation of sepsis-induced rat liver injury by epigallocatechin gallate via suppression of oxidative stress-related inflammation. *Tropical Journal of Pharmaceutical Research*. 2017;16(12):2877-2884.
- [35] Huang R, Li M. Protective effect of Astragaloside IV against sepsis-induced acute lung injury in rats. *Saudi Pharmaceutical Journal*. 2016;24(3):341-347.
- [36] Ibrahim, Y., Moussa, R., Bayoumi, A., & Ahmed, A. Tocilizumab attenuates acute lung and kidney injuries and improves survival in a rat model of sepsis via down-regulation of NF- $\kappa$ B/JNK: a possible role of P-glycoprotein. *Inflammopharmacology*, 2019; 1–16. <https://doi.org/10.1007/s10787-019-00628-y>